



PATIENT

Precious Holshouser

PRESENTING CLINICAL SIGNS

History: Heart murmur, Coughing.
-Current medications: Enalapril 2.5mg 1/2 BID.

SPECIES

Canine

ECHOCARDIOGRAM FINDINGS

2D, m-mode and Doppler imaging are available. Diffuse thickening of mitral valve leaflets (anterior > posterior) with mild prolapse into the left atrial lumen. Marked eccentric mitral regurgitation with marked left atrial dilation. Significant LV dilation with hyperdynamic myocardial function. The tricuspid valve appears mildly thickened, with mild tricuspid regurgitation. Mildly elevated velocity. Mild right atrial and ventricular dilation consistent with early pulmonary arterial hypertension. The pulmonic and aortic valves are normal in morphology and mobility. Normal pulmonic and aortic outflow velocities. No pulmonic or aortic insufficiency. No pericardial or pleural effusion noted. No cardiac tumors observed.

BREED

Shih Tzu

SEX

Female

CARDIAC CHART

AGE

12 years

WEIGHT

11.2

INTERPRETED BY

Maggie Machen Lamy,
DVM, DACVIM
(Cardiology)

CANINE CARDIAC PARAMETERS	MR VMAX (m/s)	TR VMAX (m/s)	LA/AO (Boon method)	LA/AO (Heart Base; Swe)	FS (%)	EF (%)	EPSS (cm)
NORMAL PARAMETER	4.5-5.5	<2.7	1.3	<1.6	28-40	40-100	<0.6
PATIENT	5.2	2.8	2.5	2.4	52	84	NM
CANINE CARDIAC PARAMETERS	HR (BPM)	AV VMAX (m/s)	PV MAX (m/s)	BODY WEIGHT	LA 2D short axis Base view (cm)	LVIDd Avg; 2D and m-mode short axis (cm)	LVIDs Avg; 2D and m-mode short axis (cm)
NORMAL PARAMETER	50-100	0.7-1.7	0.7-1.6	BELOW	BELOW	BELOW	BELOW
PATIENT	150	1.0	0.9	11.2	2.6	3.9	1.8
*Normal chamber parameters expressed as a mean value (SD)				3	1.27 (5.3)	2.46 (2.46)	1.36 (5.5)
BODY WEIGHT DEPENDENT PARAMETERS				5	1.40 (4.5)	2.74 (5.2)	1.60 (4.7)
<i>*Note: All measurements based upon multi-modal images and methods. An average value is reported.</i>				10	1.50 (3.8)	3.27 (3.5)	2.06 (3.1)
				15	1.83 (2.0)	3.71 (2.4)	2.43 (2.1)
				20	2.02 (1.9)	4.14 (2.2)	2.80 (2.0)
				25	2.18 (2.4)	4.48 (2.9)	3.10 (2.5)
				30	2.33 (3.3)	4.83 (3.9)	3.39 (3.4)
				35	2.48 (4.3)	5.17 (5.0)	3.69 (4.5)
				40	2.62 (5.2)	5.48 (6.1)	3.96 (5.4)
				50	2.88 (7.1)	6.07 (8.3)	4.46 (7.4)

INTERPRETATION OF THE FINDINGS & FURTHER RECOMMENDATIONS

The cause of the murmur is chronic degenerative valve disease causing marked mitral and mild tricuspid regurgitation. Severe left atrial enlargement indicates the risk for spontaneous congestive heart failure is elevated. Mild TR is also noted, with evidence of early pulmonary hypertension. No additional issues such as systolic dysfunction are identified.

IMAGING PERFORMED BY

Sands Hill Mobile
Veterinary Ultrasound

HOSPITAL NAME

Surf City Animal
Hospital

REFERRING VET

Dr. Wick

INVOICE

23373

DATE

3/31/22

The described cough is likely multi-factorial in origin, including a mechanical component due to cardiomegaly, possible concurrent airway disease and/or early CHF given the severity of disease. Screening chest radiographs are recommended. Given the symptoms and echo findings, full lifelong cardiac support is recommended as below including Lasix therapy. Depending on clinical



PATIENT

Precious Holshouser

SPECIES

Canine

BREED

Shih Tzu

SEX

Female

AGE

12 years

WEIGHT

11.2

INTERPRETED BY

Maggie Machen Lamy,
DVM, DACVIM
(Cardiology)

IMAGING PERFORMED BY

Sands Hill Mobile
Veterinary Ultrasound

HOSPITAL NAME

Surf City Animal
Hospital

REFERRING VET

Dr. Wick

INVOICE

23373

DATE

3/31/22

response to the medications, cough suppression may also be useful. **Monitoring of sleeping breathing rates in the future will be paramount to determine the origin of any future cough.** The average survival of canine patients with active pulmonary edema is 8-9 months on medications, however they generally are able to maintain a good quality of life for that period. Patient will always be at risk for recurrent CHF, development of arrhythmias/LA tear, syncope and/or sudden death in the future. Monitoring of renal values is recommended lifelong.

Omega fatty acid supplementation and mild salt restriction may also be of some long-term benefit. Monitor for development of a worsening cough, labored breathing, exercise intolerance or collapse episodes.

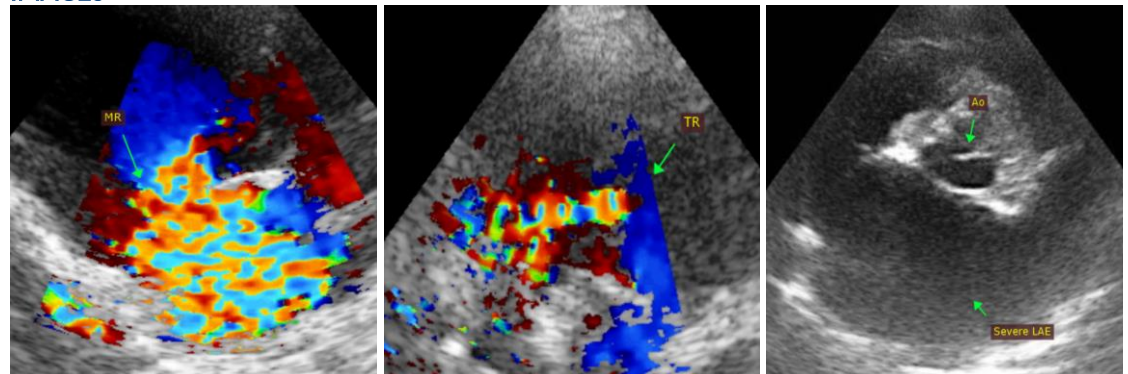
PLAN

Screening BP is recommended. Administer Pimobendan 0.3mg/kg PO q12h. Administer low dose furosemide/Lasix 1 mg/kg PO q12h. Administer spironolactone 1-2mg/kg PO q12h. Consider hydrocodone with homatropine (0.2-0.4mg/kg PO up to q4-6 hours PRN) if cough persists despite normal SRRs.

A renal panel and BP are recommended in 10-14 days, then every 3-4 months on diuretics to ensure tolerance of medications. If doing well at that time and BP >130mmHg, institute ACEI 0.5mg/kg PO q12h.

A recheck echocardiogram is recommended in 6 months to screen for progression, sooner if clinical signs arise/persist.

IMAGES



The information and recommendations provided are based on the images presented by the referring veterinarian. No evaluation can be communicated regarding pathology that was not visible in the image/video clips provided.

Thank you for this referral. This report was generated using transcription software, and minor dictation errors may be present. If the clinical or image interpretation does not parallel your findings or if I can be of any further assistance, please contact me.

Maggie Machen Lamy, DVM
Diplomate of the American College of Veterinary Internal Medicine (Cardiology)
info@sonopath.com